

Hemostatic Agents: Brain Tissue Reaction and Effectiveness

A Comparative Animal Study Using Collagen Fleece and Oxidized Cellulose

Joan H. C. Voormolen, M.D., Jan Ringers, M.D., Gerard T. A. M. Bots, M.D., Ph.D., Annette van der Heide, and Jo Hermans, Ph.D.

Departments of Neurosurgery (JHCV, JR), Pathology (GTAMB, AH), and Medical Statistics (JH), State University Leiden, The Netherlands

In a series of 26 young rabbits, three cortical lesions were made in each hemisphere. Two of these holes were filled with collagen fleece (CF) and oxidized cellulose (OC), respectively, while the third was left empty as a control. The bleeding time was measured. Hemostasis with CF was statistically significantly faster than with OC, which in turn was statistically significantly faster than with no hemostatic agent. The animals were killed successively on Days 7, 14, 28, 42, and 241 after operation. Histopathological investigation showed that CF did not induce more tissue reaction than the control lesion and that CF was resorbed faster than OC. The removal of OC occurred from the borders of the material, moving gradually inward. With CF, there was an immediate ingrowth of reactive cells throughout the material. In contrast to OC, CF did not induce the formation of polynucleated giant cells. From these results, it can be concluded that CF is a fast, safe, and absorbable topical hemostatic agent suitable for use in neurosurgical procedures. (*Neurosurgery* 20:702-709, 1987)

Key words: Brain tissue reaction, Collagen fleece, Hemostasis, Oxidized cellulose, Topical hemostatic agent

INTRODUCTION

During intracranial interventions, surgical hemostasis is attained by coagulating bleeding vessels with bipolar electrocoagulation. Low flow bleeding (oozing) is controlled by the application of various topical hemostatic materials, such as gelatin foam, oxidized cellulose (OC), thrombin-soaked materials, and saline-soaked cotton. In addition, compression is needed to achieve hemostasis. Several studies have shown that, with the use of collagen fleece (CF), a faster hemostasis can be achieved than with other materials (7, 8, 18, 19).

Properties of CF

Hemostatic effectiveness. Abbott and Austen showed in a canine arterial bleeding model that microcrystalline collagen was a superior hemostatic agent. Final hemostasis was achieved with CF in 91% of 45 lesions. The percentage was 4.4% with no agent and 42% with OC. Even with complete heparinization, the final hemostasis rate was 76%. If the animals were treated with salicylates (full salicylate effect in platelet aggregation studies), CF achieved hemostasis in 85%. In animals with thrombocytopenia caused by platelet depletion ($<10,000/\text{mm}^3$), the hemostasis rate was reduced to 71%. Another significant feature of this agent was that excess collagen could be carefully teased away from around the puncture site without initiating rebleeding. In comparison, it was never possible to remove OC without causing rebleeding.

Collostat (bovine collagen; American Medical Products Corp., Freehold, New Jersey) proved to be the most effective hemostatic agent for splenic lacerations in an animal study comparing four materials: Avitene powder (also a collagen), Collostat fleece, OC, and Gelfoam (absorbable gelatin sponge; The Upjohn Co., Kalamazoo, Michigan) (8). Using collagen in a nonwoven web form in experimental lacerations of the superior sagittal sinus in dogs, Murphy and Clough found that it was superior to patches of gelatin foam soaked in thrombin and OC (14). Pertuiset and Sichez were the first to report on the clinical use of collagen in 35 neurosurgical cases (16). They had good results.

Hemostatic action. The hemostatic activity of collagen-

derived hemostatic materials has been explained in several ways. The induction of platelet adhesion, release reaction, and aggregation is supported by the literature on collagen-platelet interaction (3, 4, 9, 11). The activation of some blood coagulation factors is favored by the studies of Engel and Alexander (10) and Mason and Read (12, 13). Mechanical tamponade of the severed vessels by the adherence of collagen material to the bleeding wound has also been suggested (19).

Tissue reaction. Animal studies dealing with collagen-derived materials clearly demonstrate that few tissue reactions occur in organs other than the brain (5, 6). In the only brain tissue study to date, no significant differences in the amount or type of tissue reaction was seen when comparing microfibrillar collagen and gelatin foam in canine brain cortex lesions at 2, 4, and 6 months postoperatively (17).

Biodegradability. The resorption of collagen material occurs by the infiltration of inflammatory cells, principally macrophages and, to a lesser extent, granulocytes (15). Both of these cell lines contain collagenase, which exists in an inactive form in resting cells. By activation of cells due to phagocytosis or lymphokines, collagenase is activated and acts extracellularly as well as intracellularly to digest collagen.

The biodegradability of collagen depends to a high extent upon the degree of cross linking or tanning (6). Animal studies show complete resorption of the collagen material (5, 6).

Because experimental evidence proves that CF has hemostatic properties superior to those of other commonly used agents, CF seems to be an ideal material for use in neurosurgery (1, 5, 7, 20). There is insufficient evidence on the brain tissue reaction to CF.

Objectives

Our objectives were (a) to compare the hemostatic potency of the tested materials by measuring the bleeding time in the presence of cerebrospinal fluid, (b) to study the reactions in rabbit brain tissue induced by a lesion in which hemostasis was achieved with CF, and (c) to compare these reactions with those in control lesions and lesions where hemostasis was achieved with OC.

MATERIALS AND METHODS

Hemostatic agents

The CF (Novacol; manufactured and supplied by Applied Collagen Science, division of the Datascope Corp., Hoevelaken, The Netherlands; submitted for FDA approval) used in this study is a pad of long, nonwoven collagen fibers derived from bovine Achilles tendons. This collagenic tissue is highly purified by means of a proprietary chemical process. The final product contains less than 0.01% lipid residues and is free of noncollagenous proteins, glycosamins, and toxic heavy metals. This material has the same characteristics as microfibrillar collagen hemostat (Avitene; Alcon Laboratories, Fort Worth, Texas). The oxidized cellulose used in this study was a commercially available product (Tabotamp or Surgicel; Johnson & Johnson, Duesseldorf, West Germany). It consists solely of regenerated oxidized cellulose.

Method

For this study, 26 young Dutch belted bred rabbits, weighing approximately 3.5 kg each, were used. These animals were housed under standard conditions ($20 \pm 2^\circ\text{C}$, relative humidity $65 \pm 3\%$, light on from 8:30 to 20:30 hours) receiving water ad libitum and 100 g of rabbit feed daily. Anesthesia was induced with 0.2 mg of fentanyl base and 10 mg of fluanisone i.m. and, after intubation with an oral Portex tube No. 3 (Portex Ltd., Hythe, Kent, England), was maintained with 1.5% halothane and 1000 ml of oxygen per minute. The animals breathed spontaneously through a Jackson-Rees system.

Preoperatively and during 1 week postoperatively, the rabbits were given a daily dose of phenytoin, 25 mg s.c., to prevent epileptic seizures. The head of the rabbit was fixed in a stereotactic device, and the femoral artery was cannulated to monitor arterial blood pressure continuously. To prevent occlusion, we administered 6 IU of heparin per hour.

With the use of normal sterile neurosurgical procedure, a bilateral parasagittal craniectomy (20×8 mm) was performed through a midline incision on the vertex using an operative microscope. After the dura mater was opened, three lesions were produced in the frontoparietal region of both hemispheres with a turning drill 2 mm in diameter to a depth of 3 mm. Immediately, two of the holes were filled with hemostatic material (Fig. 1). The third was left empty (control lesion). The sequence of the localizations of the materials, (CF, OC, or control) from frontal to parietal was changed according to a Latin square schedule. Because CF is thicker than OC, plugs of equal size were made from a 5×5 -mm piece of CF and a 5×10 -mm piece of OC. The OC weighed 1.5 mg, and the CF weighed 2.5 mg. Bleeding times were measured by continuous microscopic observation using high magnification with continuous low flow irrigation with saline. After hemostasis was achieved, observation was continued for 30 seconds to exclude rebleeding. The skin was then closed.

The animals were decapitated on Day 7, 14, 28, 42, or 241 after operation. The brains were immediately removed. Within 10 minutes, the left hemispheres were fixed in formaldehyde and the right hemispheres were snap-frozen in liquid nitrogen. Sagittal sections were made and stained. The following staining techniques were used for the paraffin sections: hematoxylin and eosin (HE), Giemsa, periodic acid-Schiff (PAS), Gomori, methenamine silver, Van Gieson, Holzer, glial fibrillary acidic protein, Lendrum's fibrin, and Perl's stain for iron. For the cryostat sections, HE, adenosine triphosphatase (ATPase), acid phosphatase, alkaline phosphatase, oil-red-O, PAS, α -naphthylesterase, Van Gieson, 5-nucleotid-

ase, lactic dehydrogenase, and Perl's staining for iron were used.

RESULTS

Bleeding time

The bleeding time could be determined in all 26 rabbits. In 1 animal, no lesions were made on the right side and, in another, because of bone bleeding, proper observation of the CF lesion in the right hemisphere could not be performed. Thus, on the right side there were 24 CF, 25 OC, and 25 control bleeding time observations. Because of the method used to determine the bleeding time, the results were rounded off to 15-second intervals. The results are summarized in Table 1.

To exclude the possibility that changes in circulation could have affected the observed bleeding times, we continuously monitored intraarterial blood pressure and heart rate in eight rabbits. In all eight animals, the circulation remained in a steady state throughout the surgical procedure.

Statistical analysis of the results demonstrated significant differences in bleeding times between the lesions with hemo-

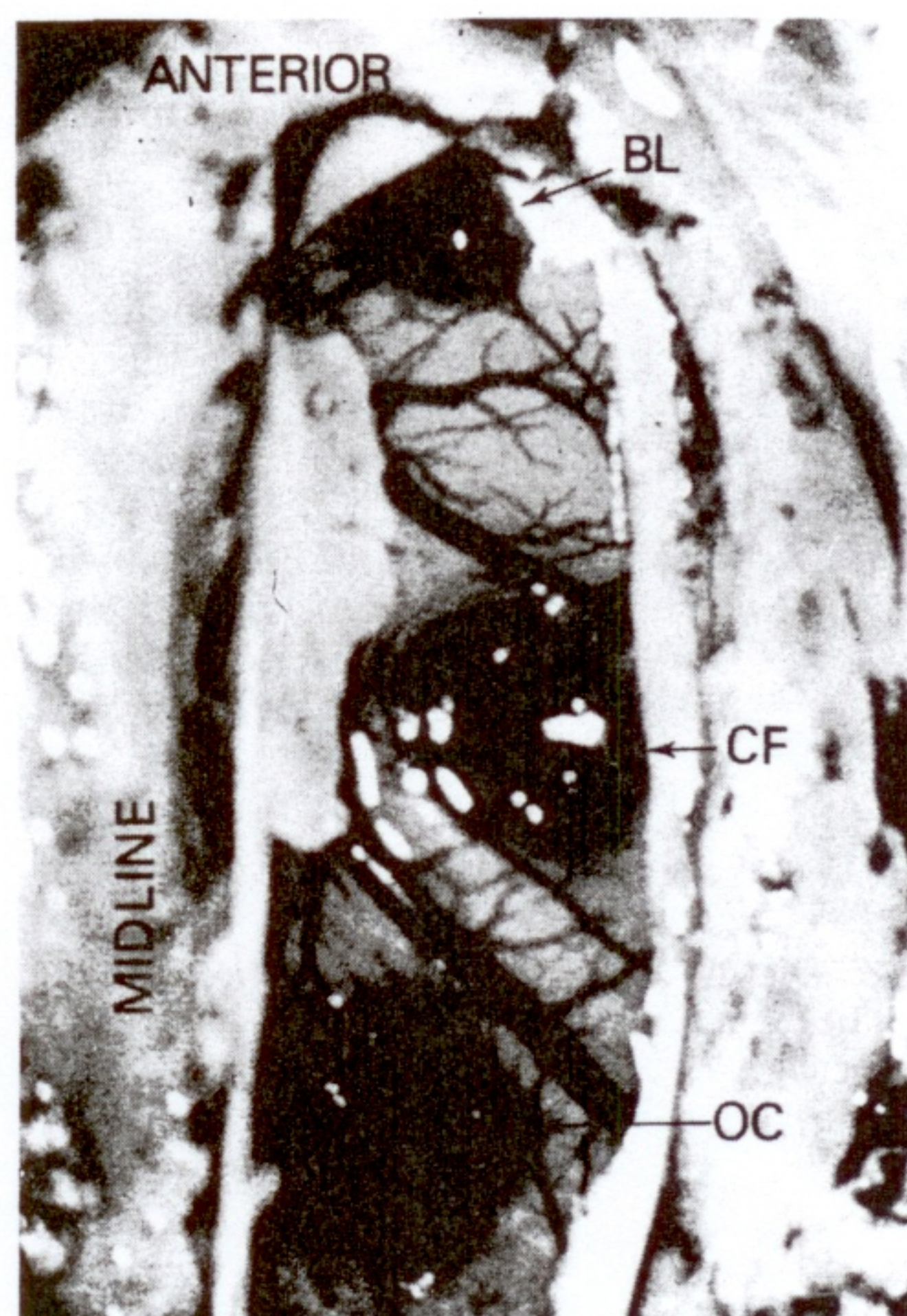


FIG. 1. Intraoperative view of the lesions filled up with CF and OC and of the control lesion. BL, control or blank lesion.

TABLE 1
Bleeding Time

Hemisphere	Lesion ^a	n	Bleeding Time (sec)		
			Minimum	Maximum	Median
Right	CF	24	45	180	90
	CL	25	120	450	210
	OC	25	60	420	150
Left	CF	26	45	240	90
	CL	26	105	735	307.5
	OC	26	45	420	135

^a CF, collagen fleece; CL, control lesion; OC, oxidized cellulose.




FIG. 2. Segment of the implanted CF after 1 week. *A*: The outer border is indicated by *arrows*. At the border, but also invading the CF, there is a proliferation of cells and capillaries. (PAS, $\times 150$.) *B*: ATPase activity demonstrates the proliferation of microglia, histiocytes, and macrophages on the border and invasion into the CF. (ATPase, $\times 150$.)

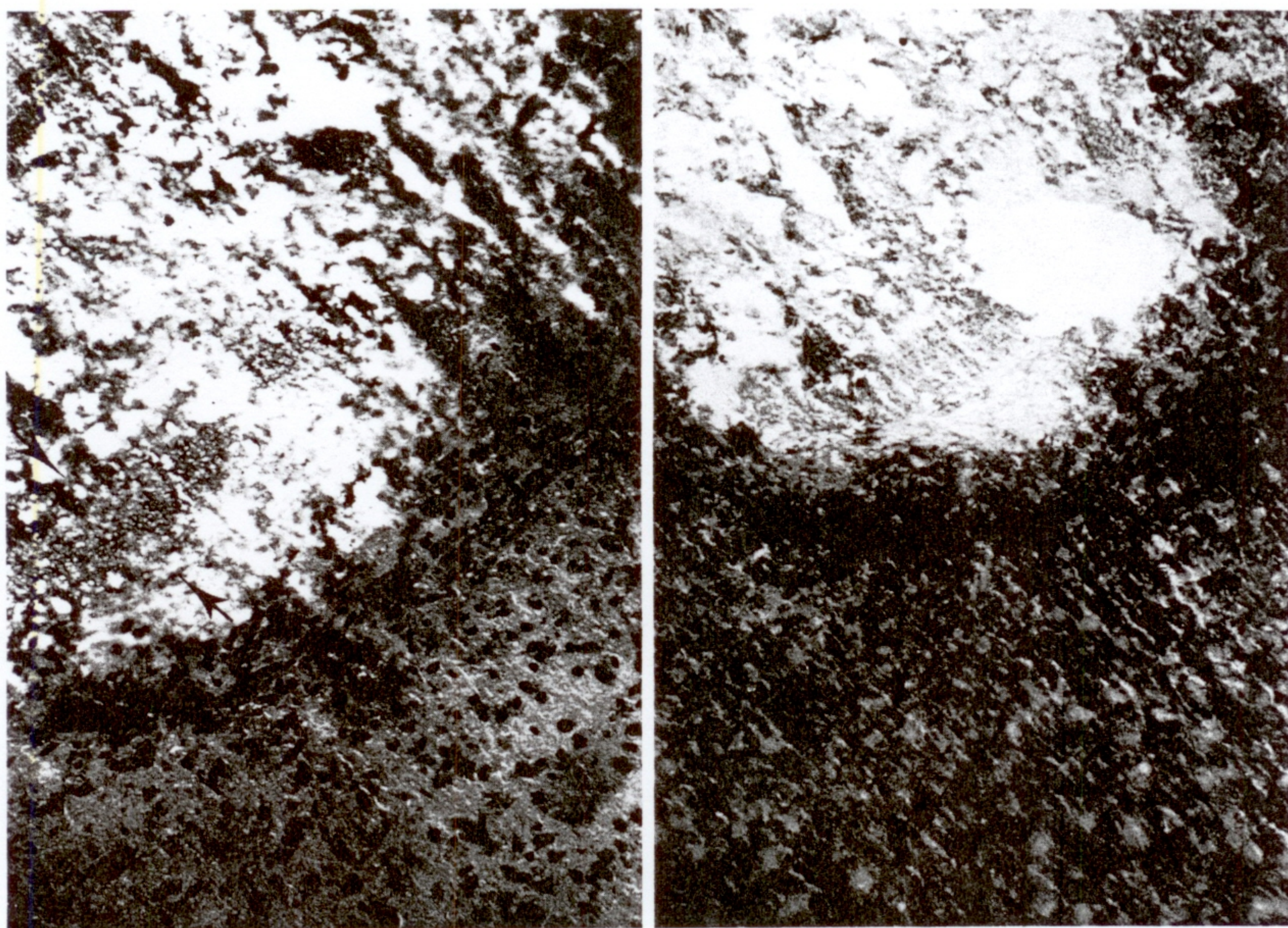


FIG. 3. Segment of the implanted OC after 1 week. *A*: Only on the border is there an indication of a proliferation of cells and capillaries. Remnants of the OC still show their structural features (*arrows*). (PAS, $\times 150$.) *B*: ATPase activity demonstrates proliferation of microglia, histiocytes, and macrophages at the border, but no invasion of the OC. (ATPase, $\times 150$.)

static materials and the control lesion ($P < 0.001$; Friedman test). A pair-wise comparison (signed-rank test) demonstrated that the bleeding time was significantly shorter with CF than with both OC ($P < 0.01$) and no hemostatic agent ($P < 0.001$). In addition, the lesion with OC had a shorter bleeding time than the control lesion ($P < 0.01$ for the right hemisphere and $P < 0.001$ for the left hemisphere). The Kruskal-Wallis test was used to check each material separately to determine whether differences in bleeding times were caused by the different locations (frontal to parietal) of the lesions. There was no evidence supporting such a supposition. The P values were 0.07 (CF), 0.38 (control), and 0.10 (OC) for the right hemisphere and 0.28 (CF), 0.87 (control), and 0.17 (OC) for the left hemisphere.

There was an important difference in the median bleeding times of the control lesions between the left hemisphere (307.5 seconds) and the right hemisphere (210 seconds). In the signed-ranks test, this difference was marginally significant ($P < 0.055$). The reason for this phenomenon has yet to be determined.

Histopathology

The brains of only 19 of the 26 rabbits could be evaluated histologically. Two rabbits prematurely died, most probably due to epileptic seizures. After the institution of phenytoin prophylaxis, no more rabbits died. In 5 rabbits, the lesions were not adequately retrievable in the sections. In 3 rabbits, only the cryostat sections and, in 2 others, only the paraffin sections could be evaluated. This resulted in 33 hemispheres for evaluation.

In all lesions, there was a tissue reaction consisting of astrocytes, microglia cells, histiocytes, and macrophages together with blood vessel neoformation. The accumulation (that is, proliferation) of these elements occurred in all three differently treated lesions. The histiocytes, macrophages, and capillaries were most pronounced at the surface near the meninges. The intensity of the reaction to the lesion seemed to be dependent not only upon the applied material, but also upon the size of the lesion. Reactive astrocytes were found more often at a distance in the surrounding brain tissue than at the border of the lesion. The microglia cells, histiocytes, macrophages, and blood vessel proliferation were seen either at the border or within the lesion itself. This was best demonstrated enzymohistochemically by ATPase activity.

After 1 week, reactive cells could be found in the center of the CF lesion, but this was seen only after 4 weeks in the OC lesion. The ingrowth of reactive cells into the CF lesion was most marked at the border, but extended throughout the material (Fig. 2). In the OC lesion, reactive cells were restricted mainly to the borders of the implanted material (Fig. 3). This indicates that CF was more rapidly resorbed than OC. In addition, after 1 week only the OC could still be recognized by its structural features.

Large macrophages and polynucleated giant cells were seen only in the OC lesions (Fig. 4). These cells were always localized in those peripheral parts of the lesion that had direct contact with the arachnoidea. After 1 week, these cells contained OC material. Later, besides some hemosiderin, there was also a granular pigment, indicating that these cells were involved in the clearance of the OC material. After 42 days, the differences among the three types of lesions began to diminish (Figs. 5 and 6). After 241 days (approximately 8 months), no difference whatever could be seen among the three types of lesions.

Differences in tissue reaction 1 week after implantation were evident when comparing the two materials. However,

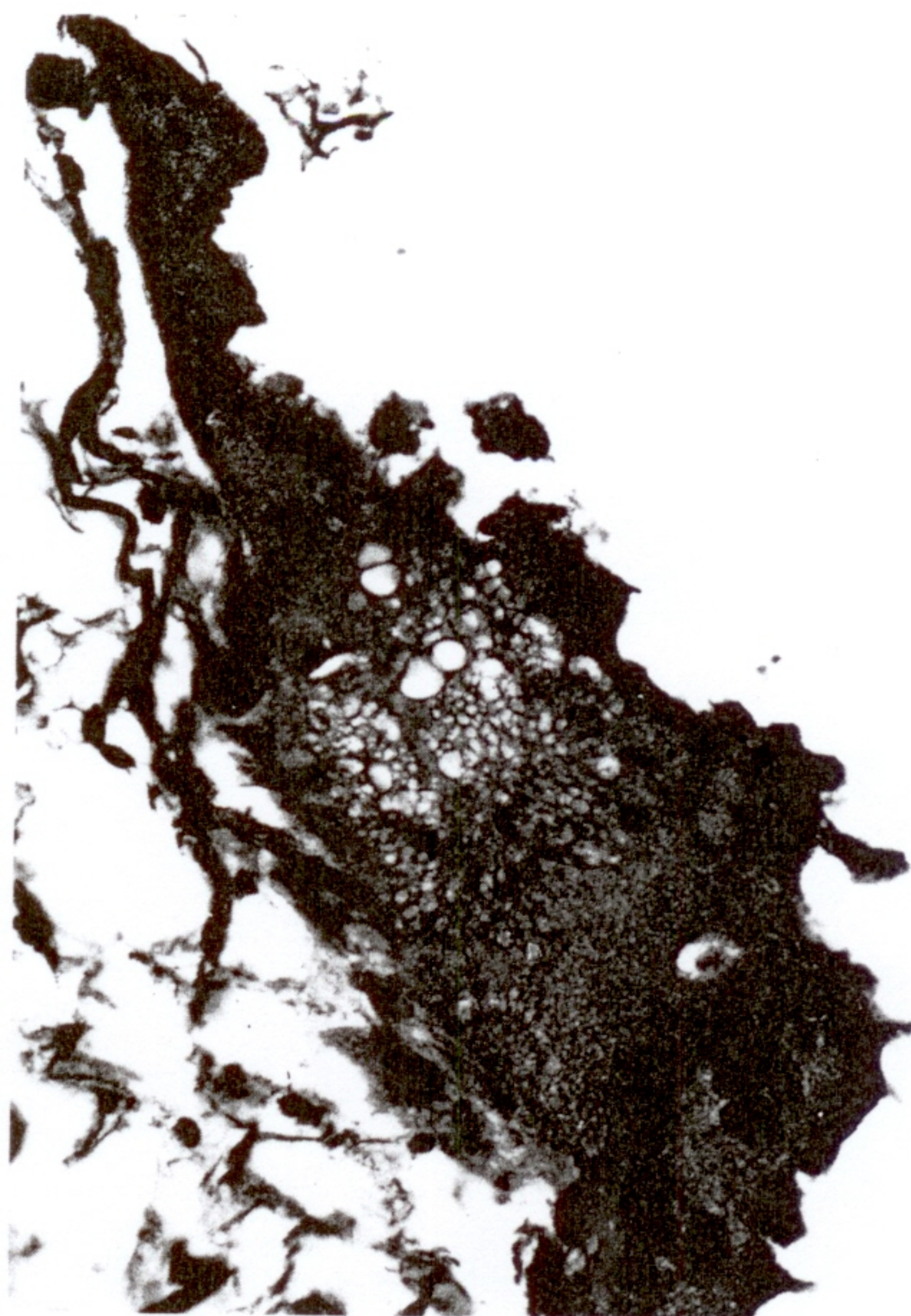


FIG. 4. Multinucleated giant cell of the foreign body type containing foamy remnants of the OC. (HE, $\times 500$.)

there was no difference in tissue reaction between the control and the CF lesions. This clear qualitative difference in the tissue reactions made it unnecessary to investigate further any quantitative differences.

DISCUSSION

In this study, CF produced a faster hemostasis than OC, indicating that it is a better-functioning topical hemostatic agent. This supports the evidence already available in the literature (1, 7, 8, 18, 19). In our study, we saw tissue reactions similar to those produced in Amon's investigation (2). Although they observed foreign body granulomas after the implantation of native collagen fleece into the subcutaneous tissue of rats, we found no foreign body granulomas in our CF lesions. Our lesions were smaller than those in the Amon's study, and our collagen was probably better purified because those authors had attributed their foreign body granulomas to sporadic fibers that were not digested by collagenase.

From our observations, it can be assumed that larger quantities of OC would be resorbed much more slowly because the resorption takes place only along the borders of the material. This was substantiated in one of our patients, in whom this material was found 5 months after operation.

In summary, CF establishes faster hemostasis than OC which, in turn, is faster than no hemostatic agent. CF does not induce more tissue reaction than the lesion alone. In contrast to the OC lesion, the CF lesion contained no polynucleated giant cells. CF is resorbed faster than OC.

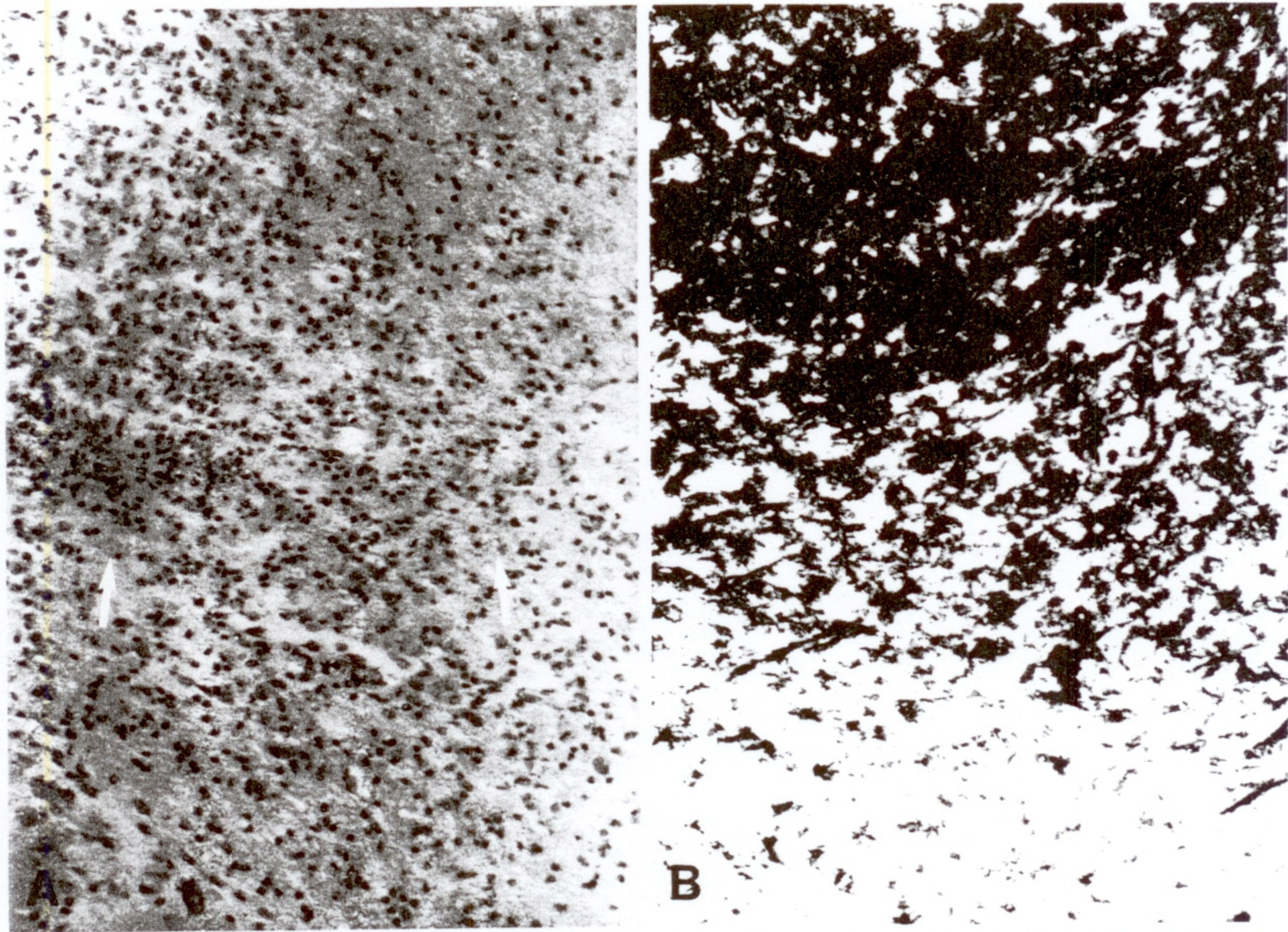


FIG. 5. Segment of the implanted CF after 6 weeks. *A*: The outer border is indicated by *arrows*. The material is invaded by cells. (PAS, $\times 150$.) *B*: ATPase activity demonstrates the proliferation of microglia, histiocytes, and macrophages within the CF. (ATPase, $\times 150$.)

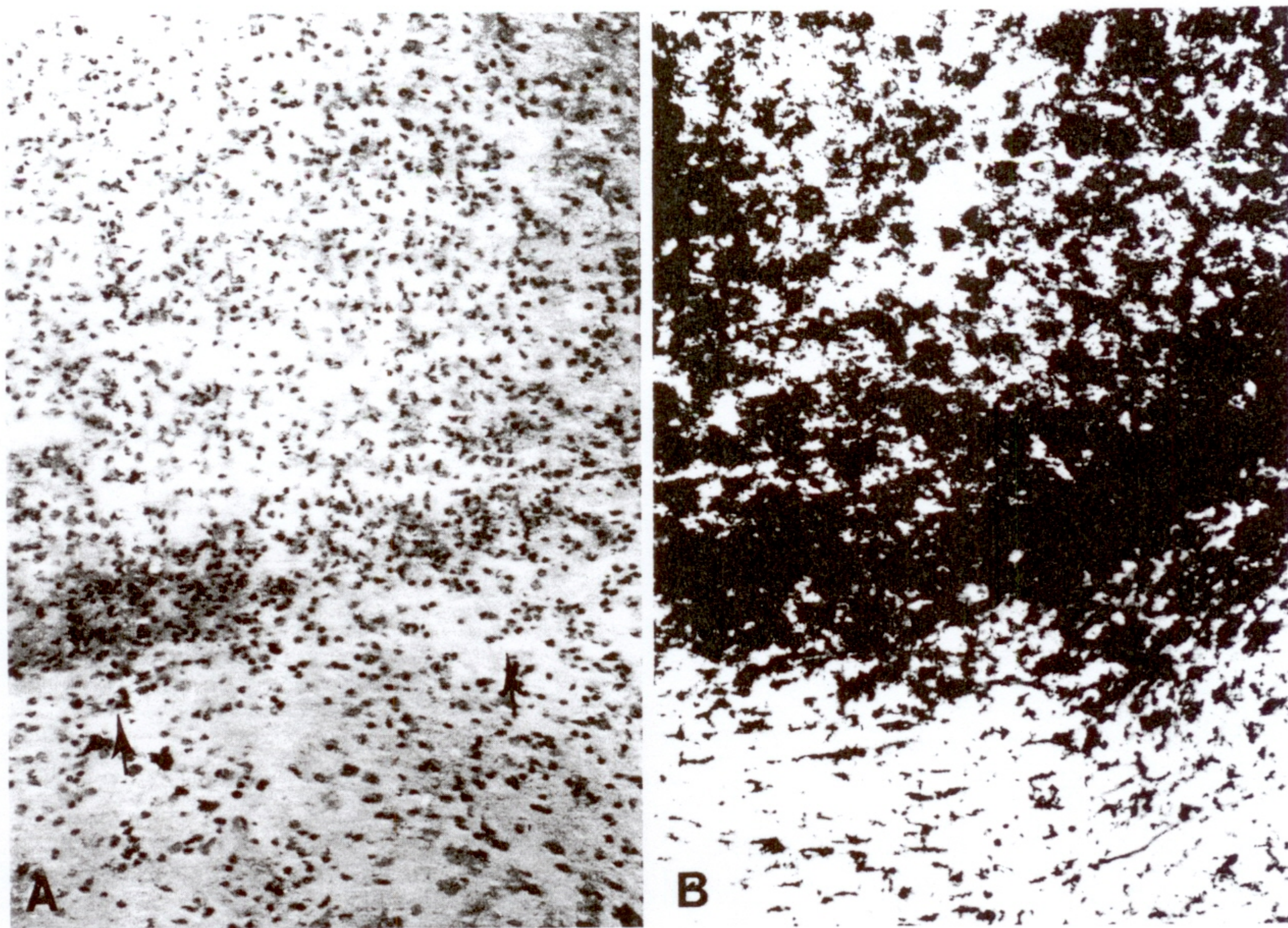


FIG. 6. Segment of the implanted OC after 6 weeks. *A*: The outer border is indicated by arrows. There is a proliferation of cells in the material. (PAS, $\times 150$.) *B*: The ATPase activity demonstrates the proliferation of microglia, histiocytes, and macrophages within the OC, but there is still some preference for the border zone. (ATPase, $\times 150$.)

ACKNOWLEDGMENTS

We gratefully acknowledge the technical assistance of Mrs. Francine Penders, Mrs. Leonie Bemelman, Mr. Jan van der Zwet, and Mr. Peter van Tilburg. B. F. Cohn, M.D., revised the English text.

This study was supported by a grant from the Datascope Inc., Hoevelaken, The Netherlands.

Received for publication, June 15, 1986; accepted, November 2, 1986.

Dr. Ringers is presently resident at the Saint Lucas Hospital, Amsterdam, The Netherlands.

Reprint requests: J. H. C. Voormolen, M.D., Afd. Neurochirurgie, Postbus 9600, 2300 RC Leiden, The Netherlands.

REFERENCES

- Abbott WM, Austen WG: The effectiveness and mechanism of collagen-induced topical hemostasis. *Surgery* 78:723-729, 1975.
- Amon H, Kirschbaum M, Petry G: Licht- und elektronenmikroskopische Untersuchungen ueber die lokalen Reaktionen auf implantiertes Kollagen-Haemostypticum—eine tierexperimentelle Studie. *Langenbecks Arch Chir* 362:167-183, 1984.
- Balleisen L, Marx R, Kuehn K: Uber die stimulierende Wirkung von Kollagen und Kollagenderivaten auf die Ausbreitung und Folienadhaesion von Thrombozyten in defibrinogenisiertem Menschencitratplasma und in tierischen Citratplasmen. *Blut* 31:95-106, 1975.
- Caen JP, Legrand Y, Sultan Y: Platelet-collagen interactions, in Brinkhous KM (ed): *Vascular Factors and Thrombosis*. Stuttgart, Schattauer Verlag, 1970, pp 181-197.
- Chvapil M: Reconstituted collagen, in Viidik A, Vuust J (eds): *Biology of Collagen*. London, Academic Press, 1980, pp 313-324.
- Chvapil M: The fate of natural tissue prosthesis, in Williams WB (ed): *Biocompatibility*. London, CTC Press, 1980, vol 1, pp 87-104.
- Chvapil M, Owen JA, DeYoung DW: A standardized animal model for evaluation of hemostatic effectiveness of various materials. *J Trauma* 23:1042-1047, 1983.
- Coln D, Horton J, Ogden ME, Buja LM: Evaluation of hemostatic agents in experimental splenic lacerations. *Am J Surg* 145:256-259, 1983.
- Cowan DH: Platelet adherence to collagen: Role of prostaglandin-thromboxane synthesis. *Br J Haematol* 49:425-434, 1981.
- Engel AM, Alexander B: Effects of collagen on fibrinolysis. *Thromb Diathes Haemorrh (Suppl)* 56:63-74, 1973.
- Kay WW, Kurylo E, Chong G, Bharadwaj B: Inhibition and enhancement of platelet aggregation by collagen derivatives. *J Biomed Mater Res* 11:365-372, 1977.
- Mason RG, Read MS: Some effects of a microcrystalline collagen preparation on blood. *Haemostasis* 3:31-45, 1974.
- Mason RG, Read MS: Effects of collagen and artificial surfaces on platelets that influence blood coagulation. *Thromb Res* 7:471-480, 1975.
- Murphy DJ, Clough CA: A new microcrystalline collagen hemostatic agent. *Surg Neurol* 2:77-79, 1974.
- Oronsky AL, Perper RJ, Schroder HC: Phagocytic release and activation of human leucocyte procollagenase. *Nature* 246:417-419, 1973.
- Pertuiset B, Sichez JP: Use of a new antihemorrhagic agent in neurosurgery: Trial in 35 cases. *Neurochirurgie* 28:41-43, 1982 (in French).
- Rybock JD, Long DM: Use of microfibrillar collagen as a topical

- hemostatic agent in brain tissue. *J Neurosurg* 46:501-505, 1977.
18. Silverstein ME, Chvapil M: Experimental and clinical experiences with collagen fleece as a hemostatic agent. *J Trauma* 21:388-393, 1981.
 19. Silverstein ME, Keown K, Owen JA, Chvapil M: Collagen fibers as a fleece hemostatic agent. *J Trauma* 20:688-694, 1980.
 20. Vistnes LM, Goodwin DA, Tenery JH, Ksander GA, Gruber RP: Control of capillary bleeding by topical application of microcrystalline collagen. *Surgery* 76:291-294, 1974.

COMMENTS

The authors have demonstrated the feasibility, effectiveness, and safety of collagen fleece as a hemostatic agent in and around neural tissue. These simple studies were designed to demonstrate the effectiveness of induction of coagulation, the influence upon repair, and the tolerance of the brain to the hemostatic agents studied. Collagen fleece was demonstrated to be satisfactory, even superior, as a hemostatic agent. The study does not address the long term consequences of the use of this agent, but there are no known long term adverse effects. Collagen fleece is a worthwhile addition to the neurosurgical armamentarium of hemostatics.

Don M. Long, M.D., Ph.D.
Baltimore, Maryland

In a study using a series of animals, the authors have attempted to demonstrate the advantages of collagen fleece vs. oxidized cellulose as a hemostatic agent in neurosurgery. Advantages of collagen fleece were faster induction of hemostasis, less tissue reaction, and faster resorption. However, differences in tissue reaction became insignificant after approximately 8 months. Therefore, this latter advantage from a practical standpoint may be only relative. Whether the use of collagen instead of oxidized cellulose might reduce the incidence of early postcraniotomy seizures in patients treated with focal hemostatic agents should be studied further in animals and humans.

A major disadvantage of use of collagen fleece has been difficulty in manipulating the agent during attempts to place it in the area of bleeding. However, newer forms of this material make it significantly easier to apply; it is now manufactured in woven form, making it similar to Gelfoam in ease of handling. Collagen seems to have advantages over Gelfoam in at least two areas: ability to remove the hemostatic agent after hemostasis occurs with less recurrence of focal bleeding and somewhat less potential mass effect at the area of application, even if the agent must be left behind.

Morris W. Pulliam, M.D.
Bethesda, Maryland